



CASE REPORT

The Use of Mini-Plates for the Treatment of a High-Angle, Dual Bite, Class II Malocclusion

Celha Borges Costa Alves¹, Maria Alves Garcia Santos Silva², José Valladares Neto³

¹Postgraduate Program in Dentistry, Federal University of Goiás School of Dentistry, Goiânia, Goiás, Brazil

²Department of Oral Diagnosis, Federal University of Goiás School of Dentistry, Goiânia, Goiás, Brazil

³Department of Orthodontics, Federal University of Goiás School of Dentistry, Goiânia, Goiás, Brazil

Cite this article as: Alves CBC, Silva MAGS, Neto JV. The Use of Mini-Plates for the Treatment of a High-Angle, Dual Bite, Class II Malocclusion. Turk J Orthod 2019; 32(1): 52-8

ABSTRACT

To present a case report of an orthodontic treatment of a high-angle, dual bite, Class II malocclusion without extractions and with the use of mini-plates. Class II malocclusion treatment protocols vary according to the morphological component of the malocclusion and the magnitude and direction of craniofacial growth. It is generally agreed that the cooperation of the patient and careful planning of anchorage are the key determinants of successful treatment. Protrusion of the upper and lower lip and a retrognathic mandible were the patient's chief concerns. The patient had learned to project her mandible forward to disguise the overjet. The patient's parents elected to correct the malocclusion with the use of bilateral infrazygomatic mini-plates. Pre-treatment condylar stabilization with an orthotic established a stable centric relation position, followed by mounting of the models on a semi-adjustable Panadent articulator. This allowed diagnosis and treatment planning from a stable condylar position and eliminated possible misdiagnosis due to the dual bite. Distal retraction and vertical control of the upper teeth enabled correction of the Class II malocclusion with minimal patient cooperation. Mini-plate-assisted treatment corrected the excessive overbite and overjet. The patient completed treatment with a stable occlusion and no longer postured her jaw forward. The parents and patient were completely satisfied with the positive treatment outcome. A 2-year follow-up confirmed the clinical stability.

Keywords: Angle Class II malocclusion, skeletal anchorage, centric relation

INTRODUCTION

Centric relation (CR) has been a provocative subject in dentistry. The position and its definition have changed over the decades from a retruded, posterosuperior condylar position to an anterosuperior condylar position, centered transversely with the articular disc correctly interposed (1). Discrepancies between CR and maximum intercuspation (CR-MI), or centric occlusion, may be considered a controversial contributory factor to the development of temporomandibular disorder (2-6). The clinical concept of orthodontic treatment to achieve CR as a preventive measure to improve disk-to-condyle relationships is not supported (7). In any case, significant discrepancies (>2 mm in sagittal and vertical planes and/or >0.5 mm in transversal planes), clinically known as a dual bite, have relevance for orthodontic diagnosis and treatment plan (8).

CR-MI discrepancies can occur in any type of malocclusion, regardless of age and gender. However, special emphasis should be given to Angle's Class II and III cases before orthodontic treatment (9). In Class II malocclusion cases, the bigger the functional shift, the greater are the changes in increased overjet, decreased overbite, mid-line discrepancies, and severity of the Class II relation (9, 10). In addition, it has been demonstrated that CR-MI discrepancies can affect cephalometric measurements (11). Several methods have been used to evaluate CR-MI discrepancies, including direct clinical evaluation, imaging, and articulator mountings (3).

The use of skeletal anchorage is an alternative for Class II malocclusions that allows for the application of force in various directions without the need for patient cooperation. The aim of this case report is to describe how an adolescent patient with a high-angle, dual bite, Class II malocclusion was treated with infrazygomatic mini-plates. The disadvantage of the use of mini-plates is their high value, and the procedure to install them is invasive.

CASE PRESENTATION

Diagnosis and Etiology

The patient was a 12-year-old female, whose menarche was reported 14 months previously. Her chief complaint was her retrognathic profile along with excessive overjet. She habitually projected her mandible forward in an attempt to camouflage the excessive overjet.

Facial analysis showed upper and lower lip protrusion (UI-S line=2.8 mm, LI-S line=3.9 mm). The upper lip protruded upwards and the

lower was everted. From the front, the face was symmetrical. Dental analysis revealed a complete Class II malocclusion of the molars and canines (Figure 1). The upper midline was to the right and the lower midline was to the left, in relation to the facial midline. There was mild crowding (3.5 mm) of the upper and lower anterior teeth (Figure 2). Initially, there were pain and discomfort of the masseter and temporalis muscles upon palpation. The manipulation of the mandible in CR revealed the existence of a CR-MI discrepancy of 4 mm on the left and 2.8 mm on the right, as measured by a condylar positioning indicator. The CR-MI discrepancy increased the divergence of facial planes, thus increasing the maxillomandibular discrepancy and making the profile convexity worse. Mounted models in CR revealed a more severe malocclusion and overjet than when evaluated in centric occlusion (Figure 3).

Good oral and periodontal health was confirmed by radiographic examination. The patient had previously reported chronic headaches. There was increased convexity of the maxilla (convexity angle=21.8°). The upper incisors were lingually inclined and retruded. The lower incisors were labially inclined. The maxillomandibular relationship was increased (ANB=10.9°) by the protrusion of the maxilla (89.1°) along with retrusion of the mandible (SNB=78.2°). The patient had a vertical facial pattern (SN.GoGn=34.7°) (Figure 4; Table 1).

Treatment Objectives

The treatment objectives for this patient were to relieve the crowding, establish a Class I canine relationship, correct the discrepancy between maximum intercuspation and centric relationship, correct the midline shift, create an ideal overbite and overjet, which was her chief complaint, and improve her facial profile.

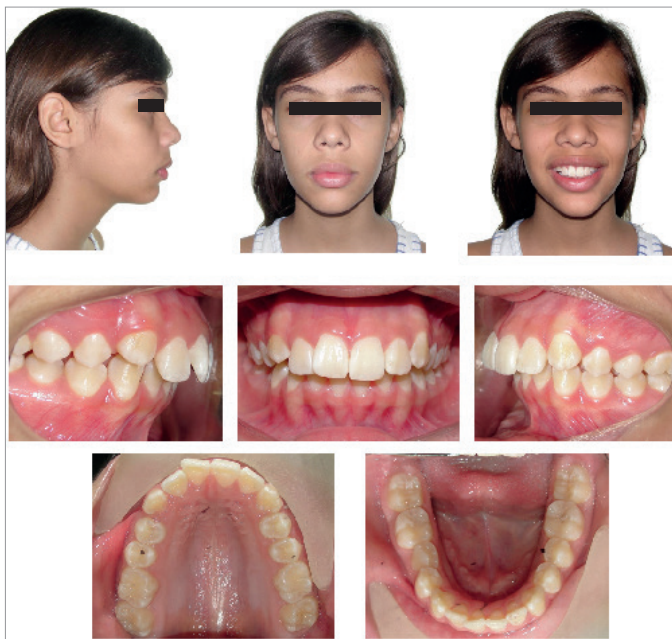

Figure 1. Pre-treatment facial and intraoral photographs

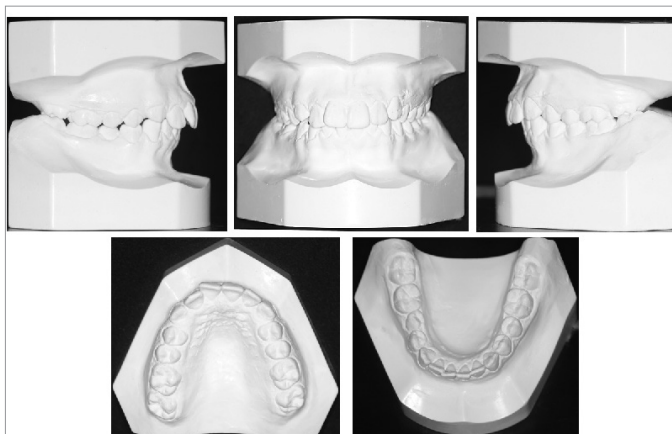


Figure 2. Pre-treatment dental casts

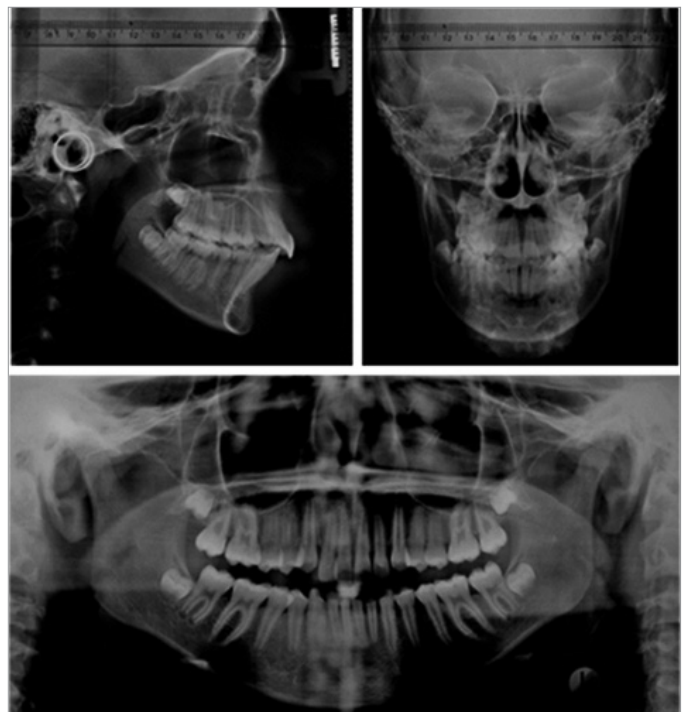


Figure 3. Pre-treatment lateral and posteroanterior cephalometric and panoramic radiographs

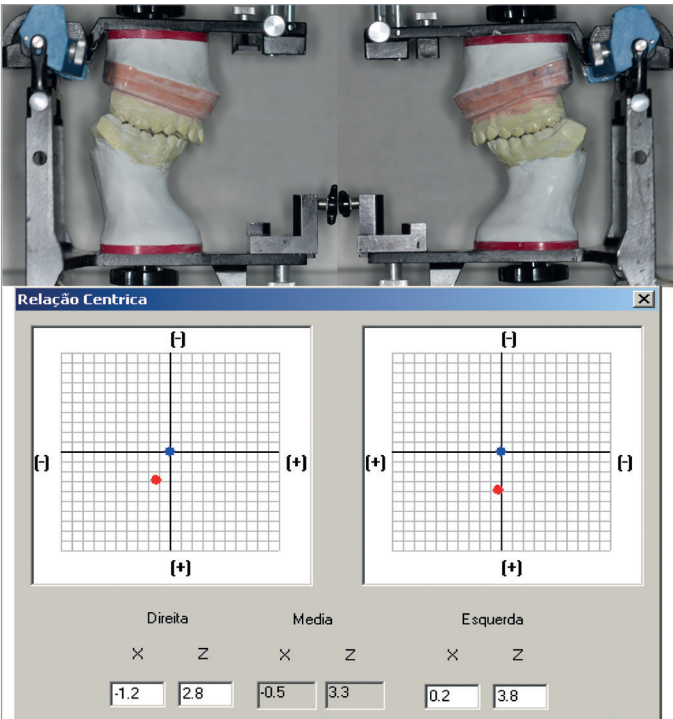


Figure 4. Mounted models on the articulator and pre-treatment CPI

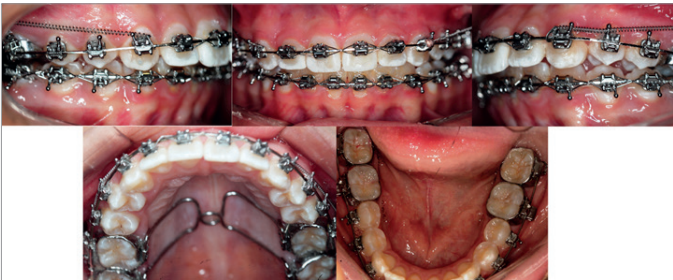

Figure 5. Photographs of the treatment

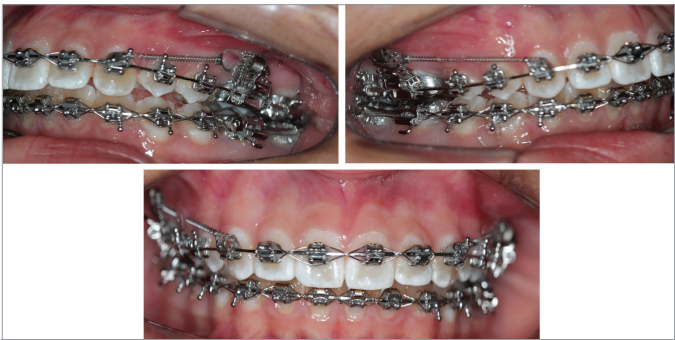

Figure 6. Photographs of mini-plates force application on both sides

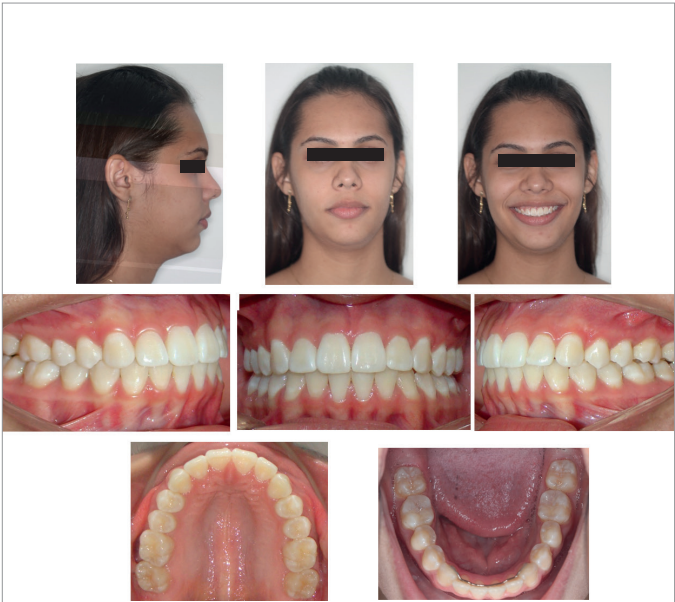

Figure 7. Post-treatment facial and intraoral photographs

Table 1. Descriptive statistics for bond strengths of orthodontic brackets in all groups

	Measures		Normal	A	B	A/B Dif.
Skeletal pattern	SNA	(Steiner)	82°	89.1°	85.0°	4.1°
	SNB	(Steiner)	80°	78.2°	77.9°	0.3°
	ANB	(Steiner)	2°	11.0°	7.01°	3.99°
	Convexityangle	(Downs)	0°	21.8°	14.1°	7.7°
	Y Axis	(Downs)	59°	60°	60°	0
	Facial Angle	(Downs)	87°	85.8°	86°	-0.2°
	SN-GoGn	(Steiner)	32°	34.7°	33.8°	0.9°
	FMA	(Tweed)	25°	29.8°	28.5°	1.3°
Dental Standard	IMPA	(Tweed)	90°	98.6°	100.1°	-1.5°
	1.NA	(Steiner)	22°	15.5°	23.6°	-8.1°
	1-NA	(Steiner)	4 mm	0.9 mm	1.7 mm	-0.8 mm
	1.NB	(Steiner)	25°	33.5°	33.3°	0.2°
	1-NB	(Steiner)	4 mm	7.9 mm	8.4 mm	-0.5 mm
	1.1-Interincisal	(Downs)	130°	120.1°	116.0°	4.1°
	1-Apo	(Ricketts)	1 mm	10.5 mm	10 mm	0.5 mm
Profile	Upper-Lip-S Line	(Steiner)	0 mm	2.8 mm	0.7 mm	2.1 mm
	Lower Lip- S Line	(Steiner)	0 mm	3.9 mm	0.0 mm	3.9 mm

Treatment Options

The patient had a vertical growth pattern and a retrusive mandibular projection. The maxilla was protrusive with a full Class II molar relationship. Treatment options to correct a Class II malocclusion include growth modification (orthopedic), orthodontic camouflage (compensatory), and an orthodontic surgical approach, with or without extraction. The viability of each therapeutic approach depends on the magnitude and direction of craniofacial growth, malocclusion severity, collaboration, and patient preference. Other factors such as airway obstruction and sleep apnea may influence a patient's treatment decision.¹⁴ Several options were discussed with the parents during consultation, including extraction and headgear, upper extractions only, and non-extraction with mini-plates. The parents were adamant that they did not want the extraction of teeth, except the third molars, if necessary. They promptly refused orthognathic surgery when raised as a treatment option.

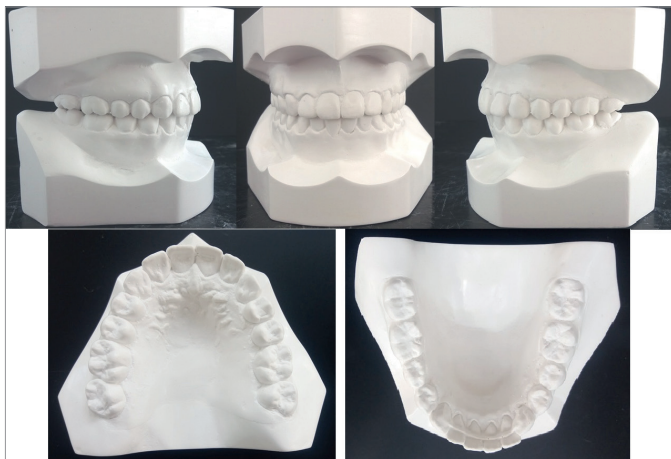

Figure 8. Post-treatment dental casts




Figure 9. Mounted models on the articulator and post-treatment CPI

Treatment Plan

An acrylic splint was first recommended for the improvement of painful muscular and headache symptoms. It was worn full-time, with weekly adjustments in the first month and then adjusted once every 15 days for the final 4 months. The adjustments helped to re-establish proper canine and incisor guidance while allowing the condyles to seat properly in the fossa. Once the patient had been de-programmed and asymptomatic for 3 consecutive weeks with no perceived or painful symptoms, even on palpation, the models were mounted back on an articulator. The final articulator-mounted models were then evaluated and a diagnosis and treatment plan determined.

A self-ligating appliance (0.022×0.028-slot Roth prescription; In-Ovation R; Dentsply GAC International Inc., USA) was deliv-

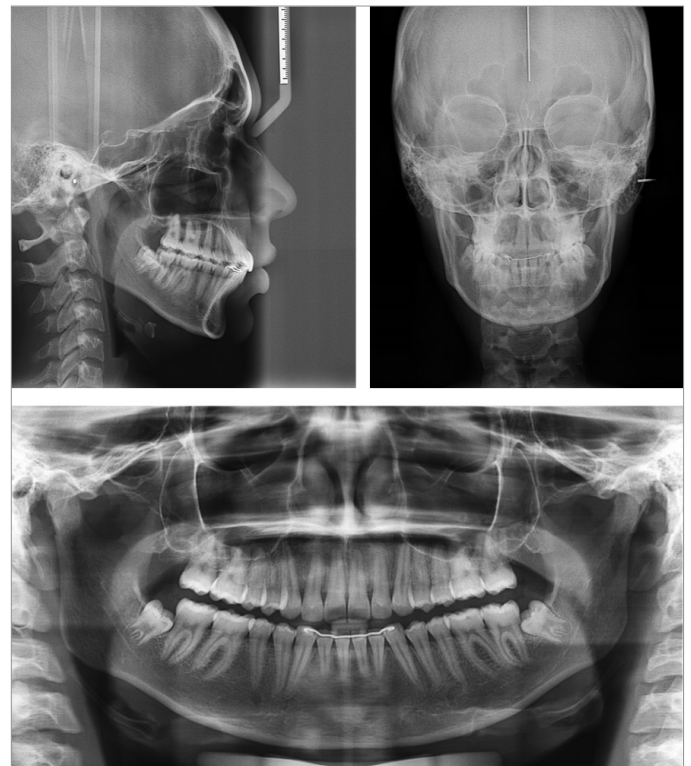


Figure 10. Post-treatment lateral and posteroanterior cephalometric and panoramic radiographs

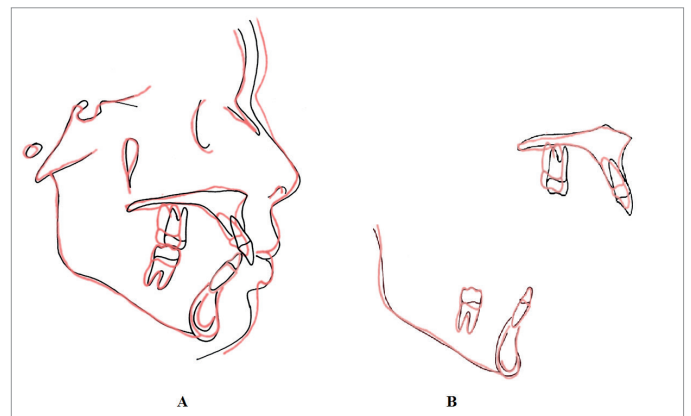


Figure 11. Superimposed tracings of the treatment (blackline) and post-treatment (red line) cephalometric radiographs. Full (A) and partial (B) overlap

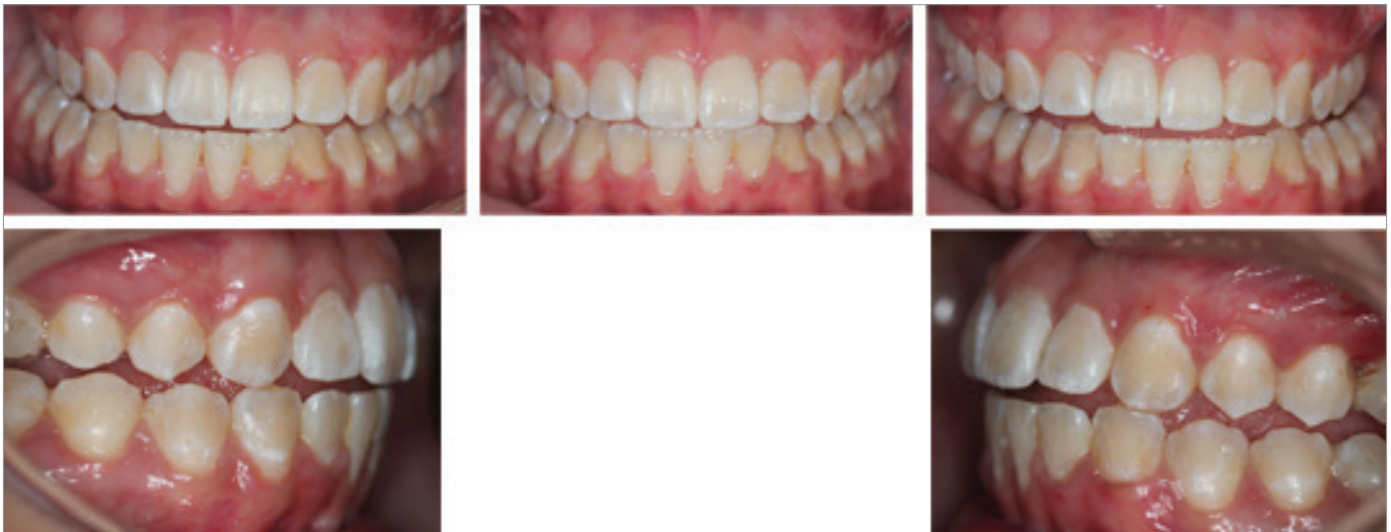


Figure 12. Anterior, right, and left canine guidance

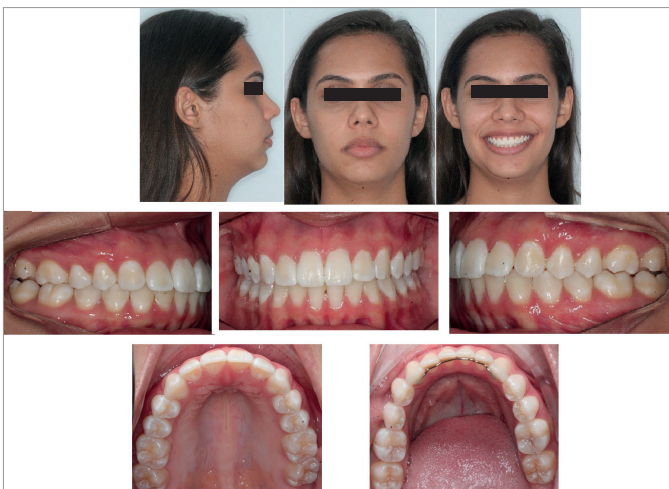

Figure 13. Two-year post-treatment facial and intraoral photographs

ered to the upper and lower arch. Transpalatal bars were placed on the first and second molars for torque control, preventing the buccal inclination of the molars. Leveling and alignment were achieved with heat-activated NiTi archwires of the following sequence: 0.014", 0.018", 0.017×0.025". Final leveling was achieved by 0.019×0.025" stainless steel wires. After leveling, the patient was referred to an oral surgeon for the placement of bilateral maxillary zygomatic mini-plates (KLS Martin® L.P.-Jacksonville, FL, USA; ortho anchorage, faceplate, open loop, straight, three holes, 9-mm BRG, T=1.0 mm, CP titanium). The patient was allowed to heal for 15 days; then, 12-mm nickel-titanium springs of 147 cN or 5.29 oz were attached over the mini-plates and to the upper archwire between the first and second molars and mesial of the canines bilaterally.

Treatment Progress

A double 0.019×0.025" stainless steel key wire was installed for retraction of the upper incisors. A 4-mm interproximal strip was placed on the lower incisors with lingual torque to correct the crowding and excessive curve of Spee. During upper molar distalization, torques were applied to control the intermolar distance

with transpalatal bars to avoid buccal proclination and crossing of the molars. After closing the spaces, study models were made for an evaluation of the maxillomandibular relationship and reassembly in the articulator. Twisted turbo 0.021×0.025" was installed intercusally with 1/8" to intermaxillary elastics (medium strength) (Figure 5). With the orthodontic treatment accomplished, the correct relationship of the molars and canines was achieved, as well as the correct canine and incisor guides in excursive movements of the jaw, with appropriate horizontal and vertical overlap. The upper and lower fixed appliances were removed and replaced by 3×3 fixed retention of the lower arch. The patient was then referred for the removal of the mini-plates.

Treatment Results

Adequate intercuspation between the maxilla and mandible was achieved with treatment, achieving alignment between the central and maximum intercuspation relationship, as seen with in the final CPI and models mounted on the articulator. A harmonious profile with significant lip improvement was observed. Correction of the relationship between the incisors provided support to the patient's lips. Correction of average midlines was achieved, achieving alignment between them. The positive treatment outcome satisfied the patient and parents, with the planned completion and treatment plan achieved (Figure 6-10; Table 1).

The final cephalometric measurements found no increases in FMA or SN-GoGn angles, indicating vertical control with mini-plates for the intrusion of the molars, observing no clockwise rotation of the mandible. Correction of the protrusion of the upper and lower lip with Class I canines and molars was achieved (Figure 9, 10; Table 1).

DISCUSSION

Several protocols are available to treat Class II malocclusion (12-15) These vary from functional appliances to orthognathic surgery, passing through molar distalization and premolar extraction. Normally, the compensatory treatment of a

vertical Class II malocclusion requires two or four premolar extractions. However, the possibility of bone anchorage has expanded the range of options for the orthodontist because it is not collaboration dependent and allows for simultaneous distalization and vertical control in cases of vertical pattern (11, 14, 16, 17). Our case report reveals the challenges of these new approaches.

A comparison of intra-arch distalizers and bone anchorage has demonstrated unwanted side effects in terms of anchorage loosening, increased overjet, molar anchorage loss during retraction, and mandibular clockwise rotation with the use of a pendulum (11). In contrast, mini-plates are not dependent on patient cooperation and enable the application of force in different directions, i.e., in three planes (anteroposterior, vertical, and transversal), with absolute anchorage control. Complex treatments become simple and predictable. The mini-plates are set well above the apexes of the teeth, which allows the application of severe orthodontic forces and the movement toward several teeth; moreover, they do not interfere with tooth movement and allow the teeth to move in the area of the mini-plate (12-14, 16, 17).

A CR-MI discrepancy in the vertical or horizontal planes increases the severity of Class II malocclusion. It is difficult to correct and is considered a risk factor for masticatory muscle pain (18). This discrepancy is better detected by mounting on the articulator (18). Mounting models in CR changes the input data collected by the orthodontist and thereby affects the orthodontic diagnosis and treatment planning. The magnitude of occlusal discrepancy in the horizontal and vertical planes is more severe when the condyles are fully seated in a high percentage of patients (8). In CR, the overjet is increased and overbite decreased compared with MI, significantly changing the diagnosis and choice of treatment (19, 20).

The critical point in deciding on the use of mini-plates in our case was the refusal on the parents' behalf in relation to orthognathic surgery and the non-option of premolar extraction, as well as the high rates of success of treatments involving mini-plates (11-15, 19). Care must be taken to prevent anchorage loss of the distalized molars during retraction of the anterior teeth. Skeletal anchorage has emerged as an effective solution to many of these problems. Among the observations made on this patient was the control of anchorage loss and no unwanted side effects of distalizing, as observed by Ishida and colleagues (13). After distalization of the maxillary molars, the Class II molar relationship was successfully corrected in this patient, as observed by Nishimura et al (14).

The pre and post-treatment superimposed radiographs showed distalization and intrusion of the upper molars and a significant improvement in the facial profile, with intrusion and improved inclination of the upper incisors. There was considerable vertical control, using mini-plates for the distalization of molars, which also prevented clockwise jaw rotation. In contrast, there was a mild anti-clockwise rotation of the mandible, with an improved facial profile (12, 13, 16, 17).

CONCLUSION

This case report shows that mini-plates enable the correction of a vertical Class II malocclusion with considerable CR-MI discrepancy by the distal movement of the upper teeth without molar extrusion. This non-extraction treatment was performed with minimal patient collaboration.

Informed Consent: Written informed consent was obtained from the patient who participated in this study.

Peer-review: Externally peer-reviewed.

Author Contributions: Concept - C.B.C.A., M.A.G.S.S., J.V.N.; Design - C.B.C.A., M.A.G.S.S., J.V.N.; Supervision - C.B.C.A., M.A.G.S.S., J.V.N.; Data Collection and/or Processing - C.B.C.A., M.A.G.S.S., J.V.N.; Analysis and/or Interpretation - C.B.C.A., M.A.G.S.S., J.V.N.; Writing Manuscript - C.B.C.A., M.A.G.S.S., J.V.N.; Critical Review - C.B.C.A., M.A.G.S.S., J.V.N.

Conflict of Interest: The authors have no conflict of interest to declare.

Financial Disclosure: The authors declared that this study has received no financial support.

REFERENCES

1. Rinchuse DJ, Kandasamy S. Centric relation: A historical and contemporary orthodontic perspective. *J Am Dent Assoc* 2006; 137: 494-501. [\[CrossRef\]](#)
2. He SS, Deng X, Wamalwa P, Chen S. Correlation between centric relation-maximum intercuspation discrepancy and temporomandibular joint dysfunction. *Acta Odontol Scand* 2010; 68: 368-76. [\[CrossRef\]](#)
3. Crawford SD. Condylar axis position, as determined by the occlusion and measured by the CPI instrument, and signs and symptoms of temporomandibular dysfunction. *Angle Orthod* 1999; 69: 103-15.
4. Weffort SY, de Fantini SM. Condylar displacement between centric relation and maximum intercuspation in symptomatic and asymptomatic individuals. *Angle Orthod* 2010; 80: 835-42. [\[CrossRef\]](#)
5. Padala S, Padmanabhan S, Chithranjan AB. Comparative evaluation of condylar position in symptomatic (TMJ dysfunction) and asymptomatic individuals. *Indian J Dent Res* 2012; 23: 122. [\[CrossRef\]](#)
6. Hidaka O, Adachi S, Takada K. The difference in condylar position between centric relation and centric occlusion in pretreatment Japanese orthodontic patients. *Angle Orthod* 2002; 72: 295-301.
7. Alexander SR, Moore RN, DuBois LM. Mandibular condyle position: comparison of articulator mountings and magnetic resonance imaging. *Am J Orthod Dentofacial Orthop* 1993; 104: 230-9. [\[CrossRef\]](#)
8. Cordray FE. Three-dimensional analysis of models articulated in the seated condylar position from a deprogrammed asymptomatic population: a prospective study. Part 1. *Am J Orthod Dentofacial Orthop* 2006; 129: 619-30. [\[CrossRef\]](#)
9. Afzal A, Shameem A. Comparison of condylar positions in centric relation and centric occlusion in pre-treatment malocclusion cases. *J Coll Physicians Surg Pak* 2005; 15: 620-3.
10. Fantini SM, Paiva JB, Rino Neto J, Dominguez GC, Abrão J, Vigoritto JW. Increase of condylar displacement between centric relation and maximal habitual intercuspation after occlusal splint therapy. *Braz Oral Res* 2005; 19: 176-82. [\[CrossRef\]](#)
11. Shildkrait M, Wood DP, Hunter WS. The CR-CO discrepancy and its effect on cephalometric measurements. *Angle Orthod* 1994; 64: 333-42.

12. Celikoglu M, Unal T, Bayram M, Candirli C. Treatment of a skeletal Class II malocclusion using fixed functional appliance with miniplate anchorage. *Eur J Dent* 2014; 8: 276-80. [\[CrossRef\]](#)
13. Ishida T, Yoon HS, Ono T. Asymmetrical distalization of maxillary molars with zygomatic anchorage, improved superelastic nickel-titanium alloy wires, and open-coil springs. *Am J Orthod Dentofacial Orthop* 2013; 144: 583-93. [\[CrossRef\]](#)
14. Nishimura M, Sannohe M, Nagasaka H, Igarashi K, Sugawara J. Non-extraction treatment with temporary skeletal anchorage devices to correct a Class II Division 2 malocclusion with excessive gingival display. *Am J Orthod Dentofacial Orthop* 2014; 145: 85-94. [\[CrossRef\]](#)
15. Nur M, Bayram M, Celikoglu M, Kilkis D, Pampu AA. Effects of maxillary molar distalization with Zygoma-Gear Appliance. *Angle Orthod* 2012; 82: 596-602. [\[CrossRef\]](#)
16. Faber J, Morum TFA, Leal S, Berto PM, Carvalho CKS. Miniplacas permitem tratamento eficiente e eficaz da mordida aberta anterior. *Dental Press J Orthod* 2008; 13: 144-57. [\[CrossRef\]](#)
17. Sakima MT. Ancoragem esquelética em ortodontia - Parte I: miniplacas SAO (Sistema de apoio ósseo para mecânica ortodôntica). *Dental Press J Orthod* 2013; 12: 8-20.
18. Lim WH, Choi B, Lee JY, Ahn SJ. Dentofacial characteristics in orthodontic patients with centric relation-maximum intercuspation discrepancy. *Angle Orthod* 2014; 84: 939-45. [\[CrossRef\]](#)
19. Almeida MR, Pereira ALP, Almeida RR, Almeida-Pedrin RR, Silva Filho OG. Prevalence of malocclusion in children aged 7 to 12 years. *Dental Press J Orthod* 2011; 16: 123-31. [\[CrossRef\]](#)
20. Hicks ST, Wood DP. Recording condylar movement with two face-bow systems. *Angle Orthod* 1996; 66: 293-300.